

# Clinical analysis of radial nerve injuries associated with fracture shaft of Humerus

Dr Krithika Kamath<sup>1</sup>, Dr Surendra U Kamath<sup>2\*</sup>

<sup>1</sup>*Kasturba Medical College, Mangalore,  
Manipal Academy of Higher Education, Manipal*

<sup>2\*</sup>*Department of Orthopaedics, Kasturba Medical College, Mangalore,  
Manipal Academy of Higher Education, Manipal*

<sup>1</sup> [krithikakk18@gmail.com](mailto:krithikakk18@gmail.com), <sup>2\*</sup> [surendra.kamath@manipal.edu](mailto:surendra.kamath@manipal.edu)

Corresponding Author: Dr Surendra U Kamath\*

## **Abstract:**

*This study aimed to find out the incidence of radial nerve palsy and to analyze results of treatment of fracture shaft of Humerus associated with radial nerve injury to improve outcome and avoid long-term morbidity. A total of eighty patients of fractures were analyzed with twenty immediate and five with secondary radial nerve palsy. Out of 25 patients, 20 were presented with primary radial nerve palsy. 18 patients recovered completely. The outcome of radial nerve palsy was not found to be related to age group, sex, side, mechanism of injury, geometry of fracture, intraoperative condition of nerve, method of treatment of fracture and time of exploration of radial nerve. Our study recommends conservative management, and a complete recovery of the nerve can be quite delayed, patience is merited before considering tendon transfers.*

*Key words: Radial nerve, Nerve Injuries, Humeral fractures, Conservative treatment, Nerve recovery*

## **Introduction:**

A radial nerve injury associated with humeral shaft fractures is an important injury pattern among trauma patients<sup>1,2</sup>. It is the most common peripheral nerve injury associated with this fracture. Injuries to the radial nerve can result in significant motor impairment of the forearm and the wrist with the loss of wrist extension, the ability to grasp is significantly reduced leading to a serious handicap. The radial nerve may be injured by the force that fractures the humeral shaft directly with contusion or laceration by a spur or by traction when the bone ends are forcibly separated during closed reduction. The risk results from the anatomic location of the radial nerve which turns around the distal portion of the humeral shaft and separated from it by a layer of triceps fibers. When the radial nerve pierces the lateral intermuscular septum to enter the anterior compartment of the arm, it is relatively more fixed and susceptible to injury. As a rule, radial palsy recovers spontaneously, but in a few cases, surgery may be required to achieve neurological recovery<sup>1,2,3</sup>.

Strong convictions for and against either line of management conservative or operative can be drawn from literature<sup>4,5,6</sup>. Opinion also differs regarding the time of surgical intervention whether to go for early or delayed repair. The newer imaging modalities-ultrasound and MRI have added a new dimension to the study of this problem. The management of radial nerve palsy associated with fractures of the shaft of the Humerus is a controversial subject among upper extremity surgeons and poses a challenge to treating surgeons. This study is attempted to find out the incidence of radial nerve palsy and to analyze results of various modalities of treatment of fracture shaft of Humerus associated with radial nerve injury to improve outcome and avoid long term morbidity.

## **Materials and Methods:**

This is a prospective observational study of eighty patients with closed and open diaphyseal fracture of humerus twenty with complete primary radial nerve palsy and five with secondary nerve palsy treated at teaching hospitals, during the period from January 2018 to September 2020. The inclusion criteria in this prospective study were diaphyseal fracture of the Humerus with radial nerve palsy developing before and after the treatment. Exclusion criteria included fractures in children, fractures of either ends of humerus and pathological fractures.

All patients with radial nerve palsy with fracture of the humerus were evaluated for various parameters mode of injury, time since injury, primary or secondary, details of any treatment received and history of any increase in the symptoms or recovery of the palsy. Local examination of the arm and fractured area to rule out any compounding and treat associated bruises and soft tissue injuries. A detailed neurological examination was performed. Antero-posterior and lateral view X-rays were done to document level and type of fracture.

The fracture was managed initially by a Plaster slab immobilization. Antero-posterior view and lateral views were taken to check the reduction. All the patients associated

with radial nerve palsy underwent open reduction and internal fixation with exploration of radial nerve. The associated wrist drop was managed by a static cock-up splint and regular physiotherapy. Wrist dorsiflexion splint dramatically improves grip strength and function. All the patients were advised passive range of motion exercise and monitored for developing contraction.

The patients were followed up at 1, 3, 6 and 12 months. At each follow up clinical signs of nerve recovery were assessed.

## Results:

A total of eighty patients of fracture shaft of humerus were analyzed in this study with twenty immediate and five with secondary radial nerve palsy. The youngest patient was 20 years and the oldest was 70 years old. Most of the patients were 21 to 40 years of age. Out of 25 patients with radial nerve palsy 16 were males and 9 were females. The most common mode of injury was fall followed by road traffic accident. Primary nerve palsy was found to be more common in our series. Out of 25 patients, 20 were presented with primary radial nerve palsy. The middle third and distal third region of Humerus shaft was involved in 96 % of patients. Oblique fracture of the humerus was found to be more commonly associated with radial nerve palsy in our series. All the cases showed the nerve to be in anatomical continuity on exploration.

We studied the relationship between recovery and age group, sex, side, mechanism of injury, geometry of fracture, intraoperative condition of nerve, method of treatment of fracture and time of exploration of radial nerve and found it to be statistically insignificant. Only one patient recovered within 6 weeks, and he belongs to the 30 to 50 age group. We found that majority of the patients in either sex took more than 18 weeks for recovery. We studied the relationship between recovery vs level of fracture and found it to be statistically significant suggesting that upper third fracture with radial nerve palsy recover faster. One patient who sustained an upper third fracture showed complete recovery in 6 weeks. In our series, 18 patients recovered completely.

## Discussion:

The fracture shaft of humerus with radial nerve palsy continues to be a management dilemma. The various electrodiagnostic studies are useful only after the process of Wallerian degeneration has set in, which usually involves a period of 3- 6 weeks. By this time, neuropraxic lesions would presumably have recovered. Moreover, electrodiagnostic studies are not able to distinguish between a severed nerve and unrecovered intact nerve and don't detect recovery much earlier than physical examination. It is therefore noteworthy that neither clinical nor electrodiagnostic studies offer any predictability of the type of nerve injury in fracture shaft humerus.

Several authors have recommended early surgical exploration, as soon as radial nerve palsy is recognized<sup>2,3,11,14,15,16,17,18</sup>. Others have recommended observation and exploration of the injured nerve only if it fails to recover after an interval of 6 weeks to 6 months<sup>5, 6, 8,10,13,16</sup>.

The incidence of the radial nerve palsy has been reported from 1.8%<sup>23</sup> to 35.3% in various studies<sup>12,13</sup>. The reported rate of poor recovery of the radial nerve function shows an amazing variation from nil (Pollock et al 1981) to 31 % (Sim et al). These results imply that surgical intervention is not necessary in most patients for good functional results. Many researchers have emphasized that in many cases, the radial nerve palsy caused by a shaft fracture is a contusion and hence exploration of the nerve is unnecessary<sup>8, 25, 36, 45</sup>. This study endeavors to answer the problems associated with this injury and sheds some light on its natural course in an attempt to suggest a rational treatment protocol for managing such injuries.

Bearing this in mind, this study was done, and the early exploration of the radial nerve with stabilization of the fracture was the main principal line of management.

The incidence of primary radial nerve palsy in our series is 25% which is high as comparable to other literature. This can be explained as our hospital is a tertiary care health centre, so it receives more complicated cases.

There are 5 cases of secondary iatrogenic palsy, 4 out of them were after plate fixation which is comparable to other studies<sup>9</sup>. 4 % of the palsies occurred in males compared to 36 % in female underscoring the more aggressive lifestyle in male which is similar to the study by Shah et al<sup>14</sup>. It also corroborated with the mode of injury in which 52% of the injuries are caused by a fall from height, 40 % from R.T.A and 4 % each from railway accident and sport injury.

The incidence of trauma was mainly in the 21-40 age groups with males predominating. This may be explained by the more aggressive lifestyle of young adults. This being the age group of money earning for the families, most of the patients were made ambulant without the aid of a support to the limb as early as possible. Due to this, patients were able to return to useful functional activities as early as possible without the presence of any support or protection to the limb, incapacitating them in their daily activities.

There was significant difference found in the radial nerve involvement with level of the fracture i.e., 4 % in upper one third, 64 % in middle one third, 32 % in lower one third of humeral shaft. This is in concordance with the study of Bostman et al<sup>5</sup>, Pollock et al<sup>8</sup>, Garcia et al<sup>18</sup>. Majority of cases of nerve palsies occurred in middle one third of the humerus shaft because radial nerve is in close contact with bone in the spiral groove at this level and at the junction of upper 2/3rd and lower 1/3rd where radial nerve pierces the lateral intermuscular septum. Hence, it is easily damaged by decreased mobility of the nerve.

Fracture pattern was oblique in 40% cases, transverse in 32 %, and spiral in 16 % and comminuted in 12 % of cases. This is in accordance with Bostman et al<sup>5</sup>. Comminution, signifying high energy absorption by the limb segment at the site of direct injury may result in direct radial nerve damage whereas the transverse fracture commonly angulated laterally may be responsible for indirectly damaging the radial nerve by either impingement by sharp fracture fragment or sudden stretching across the fracture site angulation.

Associated injuries were seen in 36% of the cases. All the associated injuries occurred mainly in road traffic accidents. Ipsilateral involvement of other bones was noted. This rate is more than the rate of 21% reported by Shah and Bhatti<sup>14</sup>. All the cases showed the nerve to be in

continuity. No surgical repair of the nerve was needed in any case which is comparable to Pollock et al<sup>11</sup>.

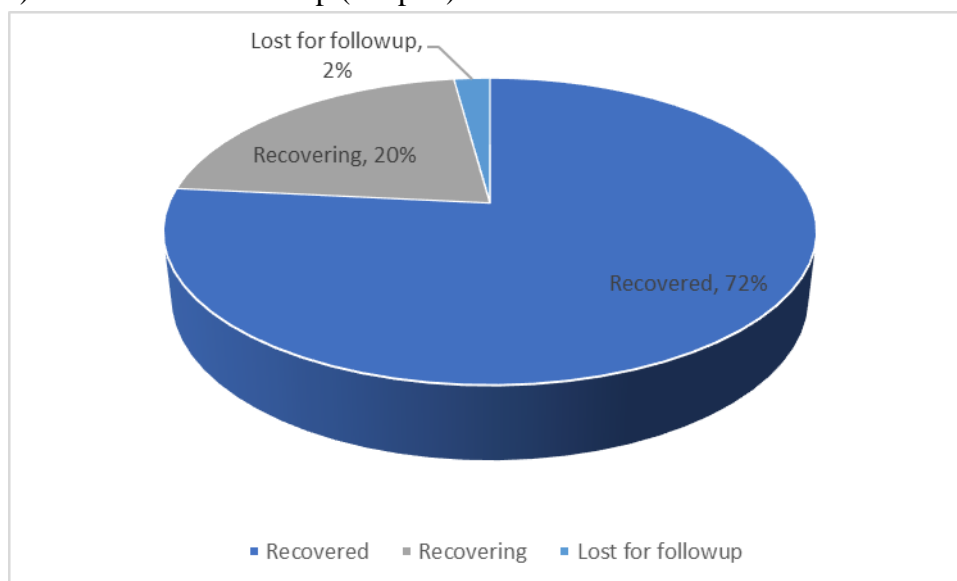
One case recovered within 5 weeks consistent with the pattern of neuropraxia while others showed recovery between 16 - 50 weeks indicating axonotmesis. The average time for completion of recovery in our study is 22 weeks while the reported incidence in literature is 15 weeks. A probable explanation for this is that most of nerve injuries sustained in our series were of axonotmesis type.

One of the patients in this study was treated by plate osteosynthesis and exploration of the nerve after 5 days of trauma. Complete recovery was noted in 5 weeks, but fracture fails to unite due to infection and implant failure. After 5 months, the patient underwent implant removal and later, treated with plate osteosynthesis and bone grafting.

Recovery of nerve function is compared according to age group, sex, side mechanism of injury, level of fracture, geometry of fracture, condition of nerve, treatment of fracture and time of exploration of radial nerve.

It was found to be statically significant for level of fracture (chi square test,  $\chi^2 = 18.073$ ,  $p$  value = .001) only. This can be explained on the basis that radial nerve is protected by thick muscle layer of triceps and relatively more mobile in upper one third than middle and lower third.

Complete recovery was seen in 72 % of the cases in our series, 20% are recovering. While two cases (8%) were lost for follow up (Graph1).



This is comparable to overall incidence of recovery, which comes out to be 77.7 % when results of previous studies are analyzed. The rate of recovery as per literature for immediate early exploration varied for different authors from 78% for Garcia and Maeck, 64% for Kettelkamp and Alexander, 73% for Shaw and Sakellarides, 89% for Packer et al to 92 % for Pollock et al.

Our observations and results support a conservative line of management as advocated by Lewis et al, Shaw et al, Pollock et al, Shah et al, Bostman et al, Larsen et al and Shao et al.

No surgically correctable lesions of radial nerve were found in our series. An early exploration may jeopardize the process of regeneration and result in delay or cessation of recovery. This could be due to additional surgical trauma inflicted during exploration along

with vascular compromise that may occur during mobilization. The fracture shaft of the humerus should be treated conservatively and an osteosynthesis, if required should be done after the recovery of radial nerve function.

### **Conclusion:**

Radial nerve palsy was more commonly seen in fractures involving the middle third of humeral shaft. The incidence of radial nerve palsy was highest in patients with oblique fracture. Average time of recovery was 22 weeks. All the cases that were explored showed the nerve to be in continuity and no surgical repair of the radial nerve was required. Radial nerve palsy associated with upper third fracture recovers faster; though it needs to be further confirmed as the sample size was small.

The outcome of radial nerve palsy was not found to be related to age group, sex, side, mechanism of injury, geometry of fracture, intraoperative condition of nerve, method of treatment of fracture and time of exploration of radial nerve. As there was no case of neurotmesis, this conclusion needs to be verified with respect to the same. Our study recommends a conservative and expectant line of management for both primary as well as secondary nerve palsies. As complete recovery of the nerve can be quite delayed, patience is merited before considering tendon transfers.

### **References:**

1. Alnot J Y, Le Reun D. Traumatic lesions of the radial nerve of the arm. *Rev-Chir-Orthop* 1989; 75(7): 433-42.
2. Alnot J, Osman N, Masméjean E, Wodecki P. Lesions of the radial nerve in fractures of the humeral diaphysis. *Apropos Of 62 Cases.Rev Chir Orthop ReparatriceAppar Mot.*2000 Apr; 86(2): 143-50
3. Amillo S, Barrios RH, Martinez-Peric R, Losada JI. Surgical Treatment of the radial nerve lesions associated with fractures of the humerus. *J Orthop Trauma.* 1993; 7(3): 211-5.
4. Laurent A. M. Hendrickx, Nick F. J., Hilgersom, Hassanin Alkaduhimi · Job N. Doornberg, Michel P. J., van den Bekero. Radial nerve palsy associated with closed humeral shaft fractures: a systematic review of 1758 patients *Archives of Orthopaedic and Trauma Surgery* (2021) 141:561–568.
5. Bostman O, Bakalim G, Vainionpaa S, Wilppula E, Patiala H and Rokkanen P. immediate radial nerve palsy complicating fracture of the shaft of the humerus, when is early exploration justified? *Injury* 1985; 16(7):4199-502.
6. De Franco MJ, Lawton JN. Radial nerve injuries associated with humeral fractures. *Journal of Hand Surg* 2006 Apr; 31A:655-63.
7. Di-Filippo. P; Mancini G B.; Gillio. A. Humeral fractures with paralysis of the radial nerve. *Arch-Putti-Chir-Organi-Mov* 1990; 38(2): 405- 409.
8. Holstein A, Lewis G. Fractures of the humerus With Radial Nerve Palsy. *J Bone Joint Surg* 1963; 48A: 1382-1388.
9. Larsen LB, Barfred T. Radial nerve palsy after simple fracture of the humerus. *Scand J Plast Reconstr Surg Hand Surg* 2000; 34(4):363-366.

10. Packer JW, Foster RR, Garcia A, Grantham SA. The Humeral Fracture with Radial Nerve Palsy: Is Exploration Warranted? *Clin Orthop* 1972; 88:34-38.
11. Pollock. F. H, Drake. D, Bovill E. G, Day. L, Trafton P. G. Treatment of radial neuropathy is associated with fracture of the humerus. *J Bone Joint Surg* 1981; 63A: 239-243.
12. Samardzic. M; Grujicic. D. and Milinkovic. Z. B. Radial nerve lesions associated with fractures of the humeral shaft. *Injury* 1990; 21(4): 220-2.
13. Sim F H, Kelly P J and Henderson E D. Radial nerve palsy complicating fractures of the humeral shaft. *J Bone Joint Surg* 1971; 53A: 1023- 1024.
14. Shah JJ and Bhatti NA. Radial nerve paralysis associated with fractures of the humerus: A review of 62 cases. *Clin Orthop* 1983; 172:171-176.
15. Shao YC, Harwood P, Grotz MR, Limb D, Giannoudis PV. Radial nerve palsy associated with fractures of the shaft of the humerus: A systematic review. *J Bone Joint Surg* 2005 Dec; 87B:1647-52
16. Shaw J L and Sakellarides H. radial nerve paralysis associated with fractures of the humerus. A review of forty five cases. *J Bone Joint Surg* 1967; 49A: 899-902.
17. Sim F H, Kelly P J and Henderson E D. Radial nerve palsy complicating fractures of the humeral shaft. *J Bone Joint Surg* 1971; 53A: 1023- 1024.
18. Takami H, Takahashi S, Ando M. Severance of the radial nerve complicating transverse fracture of the mid- shaft of the humerus. *Arch Orthop Trauma Surg*, 1999; 119:109-111.
19. Vansteenkiste.F. P, Rommens.P. M. and Broos. P. L. Is a radial nerve paralysis in a humeral shaft fracture an indication for surgery? *Acta.Chir- Belg.*; 1989; 89(4): 215-220.
20. T. R. Schwab,P. F. Stillhard, S. Schibli, M. Furrer, C. Sommer Radial nerve palsy in humeral shaft fractures with internal fixation: analysis of management and outcome *Eur J Trauma Emerg Surg* (2018) 44:235–243