

Review on Mucormycosis-After COVID-19

M. Indhumahty¹, VE. Jayanthi²

¹Assistant Professor, ²Professor, Department of Biomedical Engineering, PSNA College of Engineering and Technology, Dindigul-624622.
indhuharan@psnacet.edu.in, jayanthi.ramu@gmail.com

Abstract—

Mucormycosis is commonly known as black fungus disease. This disease principally targets diabetic and immunocompromised patients. The main purpose of this review article is to create awareness and to get preventive measures for Mucormycosis. From this, immediate treatment is required for affected person. Symptoms, causes and analysis are investigated to know the individual is impacted for Mucormycosis after COVID.

Keywords: *Mucormycosis, Fungal Infection, COVID-19, Pandemic.*

1. INTRODUCTION

The previously known instance of mucormycosis was potentially one depicted by Friedrich Küchenmeister in 1855. The sickness has been accounted for in catastrophic events. From, 2004 Indian Ocean wave and the 2011 Missouri twister. During the COVID-19 pandemic, a relationship among mucormycosis and COVID-19 are reported. Mucormycosis, is a genuine contagious uncommon disease and it is easily spread in various Covid-19 patients. While there is no significant episode, the public Covid team has given a warning [1]. The sickness frequently appears in the skin and furthermore influences in lungs and cerebrum. Mucormycosis mostly affected in the face as a dark growth and it is recognized from Covid-19 patients in certain states. Recently, mucormycosis cases recognized in Delhi, Maharashtra and Gujarat, specialists in the public Covid-19 team. Nearly 9000 patients are suffered by this infection in the year 2021. The government is taking steps to forestall the spread of this infection. Based on recent cases, men are mostly affected and they are in risk condition. From CDC survey, It is estimated that half of affected patients are died and some are saved by the removal of their eyes [2][3]. A person may suffer a lot of damage if they come in contact with this infected person. By the way, this virus is present everywhere. The fungus causes this infection and it is found in soil, trees, vegetables, animals, rotting organic matter. It is also spread in new plant grown in the infected soil or manure from decayed leaves [4]. Around 14,44,000 of its species are giving impact on our daily lives. However, only a few of these are harmful to humans such as *Candida*, *Aspergillus*, *Cryptococcus*, *Histoplasma*, *Pneumocystis*, and *Mucormycetes* are harmful to humans. The dark organism illness or Mucormycosis is an uncommon obtrusive contagious disease which has a higher death rate in the event that not analyzed well. The vascular tissue of endothelial cells is normal objective of Mucorales. There are six types of Mucormycosis in light of physical limitation, for example, rhinocerebral, pneumonic, cutaneous, gastrointestinal, spread, and different. Patients on treatment for iron over-burden are more disposed to get dark parasite [5][6]. The major problem due to mucormycosis, causes a severe pandemic while there is a great disaster named COVID-19. This diseases were termed as deadly fungal infection that leads a person to death when it is not treated properly. By, considering this, we made a researchers reviews with a tabular column which gives the causes and a precaution that can prevent this fungal disease.

In this review paper, Symptoms for identifying mucormycosis disease, the way of spreading and source of the infections are discussed in section 2. Preventing measures of this fungus are described in section 3, Treatment are elaborated in section 4 and in section 5, the analysis and Confirmation of the black fungus are discussed. The conclusion is at the section 6.

2. SYMPTOMS AND DISEASE SPREAD

Even though uncommon, it is a significant contamination. It is brought about by a gathering of molds known as mucormycetes present normally in the climate. The disease fundamentally influences people who are taking drugs for medical issues that lessens their capacity to battle ecological microbes [7][8]. Sinuses or lungs of such people get impacted after they breathe in

parasitic spores from the air. Specialists in certain states have noticed an ascent in instances of mucormycosis among individuals hospitalized or recuperating from Covid 19, with some requiring earnest medical procedure [9].

2.1 Symptoms

The following are the symptoms of Mucormycosis, agony and redness around the eyes or nose, with fever, cerebral pain, hacking, windedness, horrendous retches, and changed mental status. As per the warning, contamination with mucormycetes ought to be suspected when there is: Sinusitis - nasal bar or clog, nasal release (blackish/ridiculous), Neighborhood torment on the cheek bone, uneven facial agony, deadness or expanding, Blackish staining over scaffold of nose/sense of taste, Slackening of teeth, jaw association, Obscured or twofold vision with torment, Apoplexy, rot, skin sore, Chest torment, pleural emanation, deteriorating of respiratory indications. Specialists exhort that one ought not count all instances of obstructed nose as instances of bacterial sinusitis, especially with regards to immunosuppression or potentially Covid-19 patients on immunomodulators, Although uncommon, it is a significant contamination [11][12]. It is brought about by a gathering of molds known as mucormycetes present normally in the climate. It is generally impacts people who are consuming medications for medical conditions that decreases their capacity to battle ecological microorganisms, say specialists from the Covid-19 team. Sinuses or lungs of such people get impacted after they breathe in parasitic spores from the air. Specialists in certain states have noticed an ascent in instances of mucormycosis among individuals hospitalized or recuperating from Covid 19, with some requiring critical medical procedure [13]. Typically, mucormycetes doesn't represent a significant danger to those with a solid invulnerable framework.

2.1.1 Source of Infection

The dark yeast *Exophiala dermatitidis* is known from the climate. In Southeast Asia lethal cerebral diseases are noted in patients which are generally healthy [14]. Notwithstanding, the dominant clinical picture in Europe is subclinical colonization of the lungs of patients with cystic Fibrosis (CF); the uncommon fundamental cases in this area of the planet are gentle and happen in immunocompromised patients as it were. The disease are mostly identified by polymorphic DNA (RAPD) [15][16]. The inquiry is whether *E. dermatitidis* is a contaminant: opportunistic organism just, as may be finished up from its European event, or regardless of whether it ought to be viewed as a foundational microorganism, as appears to be evident from its conduct in Southeast Asia [17][18].

2.2 Discussion on Disease Spread With Certain Cases

Whenever found in the current condition, this contamination is observed more in patients experiencing crown or who have been relieved. Overall language, this Black Fungus contamination Causes are a large number. As indicated by certain specialists it is likewise called shrewd contamination. The rule avocation for its entry into the body is likewise the debilitating of your body's safe framework [19]. This disease generally targets people whose resistance is frail. People of a debilitated safe framework are at more serious danger of getting

contaminated with this growth. This Black Fungus Infection is accounted for to be hazardous for most diabetics. Patients with high iron or taking deferoxamine may likewise be tainted with the infection [20]. Steroid medication debilitates human insusceptible framework by bringing down glucose, which is exceptionally positioned in Black Fungal Infection Causes. Its more noteworthy impact is being found in patients experiencing Covid 19. In these patients, because of crown, the ability to battle against sicknesses is diminished, that opens the way for the infection called mucormisates to enter your body [11]. This dark parasite causes the veins their objective when they to enter the body, because of which the course of tissue rot begins. This contamination is additionally normally present in the air, which can enter your body through the air. We propose you wear masks consistently [21][22][23].

The dark organism illness or Mucormycosis which is an uncommon intrusive contagious contamination which has a higher death rate in the event that not analyzed well. The vascular tissue of endothelial cells is normal objective of Mucorales[24]. There are six types of Mucormycosis in light of physical restriction, for example, rhinocerebral, pneumonic, cutaneous, gastrointestinal, spread, and random. Patients on treatment for iron over-burden are more inclined to get dark organism. There are a few ailments of people who are more disposed to created mucormycosis for instance ineffectively controlled diabetes mellitus, hematological malignancies with neutropenia, strong organ relocate beneficiaries, hematopoietic immature microorganism relocate beneficiaries, rheumatic or immune system illness, chemotherapy or immunosuppression, peritoneal dialysis, human immunodeficiency infection contamination, lack of healthy sustenance, over-burden of iron in body, consumes, injury and individuals who utilized voriconazole as a medicine in the past[25]. The investigation likewise gives bits of knowledge on the sort of treatment these patients got during their Covid-19 treatment. Mucormycosis has turned into a significant test for the organization which is presently battling to treat patients for both the contaminations, mucormycosis and Covid-19. The examination of the relative multitude of cases enrolled on the wellbeing office entrance gives the quantity of individuals who have gotten steroid treatment and oxygen support, fundamental during the treatment of Covid-19[26]. These treatment conventions are currently being addressed as potential reasons for mucormycosis. Mucormycosis, which is an organism, has now turned into a significant test due to the quantity of diseases detailed.

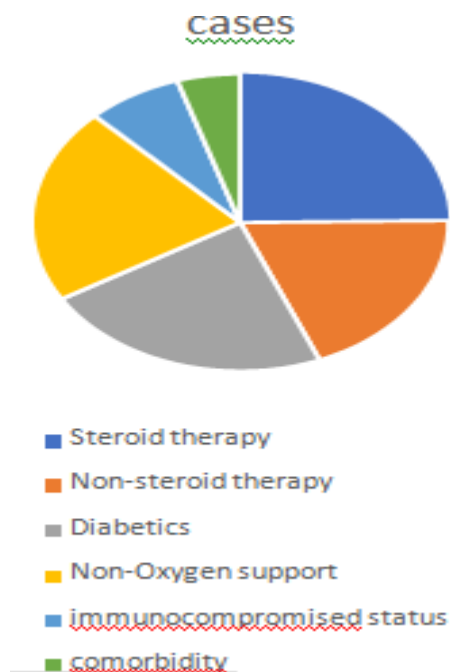


Fig. 1 Stastical data on the treatment of mucormycosis.

The major discussions are carried upon, on the basis of 620 cases, 351 sought steroid treatment, while 269 didn't seek steroid treatment. Additionally, 302 individuals didn't get oxygen support preceding the beginning of mucormycosis. The data similarly shows, that from 620 cases, 380 had diabetes. This table was trailed by 105 who had an immunocompromised status and 69 who had a comorbidity[27].

A Diabetes mellitus

People with deficiently controlled diabetes mellitus which is related with especially chemotaxis, intrinsic invulnerability imperfections, phagocytosis and macrophages are exceptionally vulnerable for securing mucormycosis. Diabetics in relationship with ketoacidosis are at higher danger of creating rhino-cerebral mucormycosis[28]. In the event of diabetic patients, the normal site of disease is sinuses, yet it can without much of a stretch spread deep down, circle and mind of the patients. Diabetic patients with organ relocate or hematological malignancies, scattered or pneumonic mucormycosis disease are extremely uncommon [29].

B Non- steroid & steroid therapy

Intense respiratory pain condition is a typical difficulty of serious viral pneumonia, for example, flu and COVID-19, that requires basic consideration including ventilatory help, utilization of corticosteroids and other adjunctive treatments to capture the chaperon monstrous aviation routes aggravation. In spite of the way that recommended for the treatment of viral pneumonia, steroid treatment gives off an impression of being a double edged blade, inclining patients toward optional bacterial and obtrusive parasitic contaminations (IFIs) by which affecting dreariness and mortality. Mucormycosis is a contagious crisis with a profoundly forceful propensity for adjoining spread, related with a helpless visualization in the event that not quickly analyzed and made due. Traditionally, uncontrolled diabetes mellitus (DM) and other immunosuppressive conditions including

corticosteroid treatment are realized danger factors for mucormycosis [30]. Upon the foundation lung pathology, insusceptible brokenness and corticosteroid treatment, patients with extreme viral pneumonia are probably going to foster IFIs like aspergillosis and mucormycosis. Eminently, the blend of steroid treatment and DM can expand immunosuppression and hyperglycaemia, expanding the danger of mucormycosis in a powerless person. Here, we report an instance of sinonasalmucormycosis in a 44year old lady with hyperglycaemia optional to ineffectively controlled diabetes following dexamethasone treatment on a foundation of flu pneumonia and survey 15 accessible written works on revealed instances of flu and COVID19 relatedmucormycosis [31].

C. Comorbidity

With nonstop crisscrossing in the forecast, the board, sequelae, confusions and pathophysiology, the Covid sickness2019 (COVID-19) is as yet beating the world savagely. Starting manifestations included beating hack and prevalentpyrexia with issues in the various organs prompting breath inadequacy, smell and taste hardship, summed up inconvenience, looseness of the bowels, extreme cardiovascular harm and contaminations. Successful and ideal treatment can be gotten by diagnosing the manifestations at its previous stage, and Otorhino-laryngological review are prevalently connected with COVID-19 since the start by means of gathering the swab tests from the nasopharyngeal district to recognize the cases, to proclaim loss of smell like the exemplarside effect and to choose the infection from the depression of the center ear. Thus, they have a Comorbidity (at least two infection present ata concurrent time)[32][33]

3. IMMUNOCOMPROMISED STATUS

Immuno compromised is brought about by openness to mucor form which is generally found in soil, plants, fertilizer androtting foods grown from the ground. It is omnipresent and found in soil and air and surprisingly in the nose and bodily fluid of solid individuals, said by the trained professionals. It impacts the sinuses, the frontal cortex and the lungs and can be unsafe in diabetic or truly immune compromised individuals, as dangerous development patients or people with HIV/AIDS[34].

4. NON OXYGEN SUPPORT

While uncontrolled diabetes and utilization of high portion steroids, which stifle invulnerability, have been distinguished as the essential variables behind the instances of dark growth or mucormycosis, specialists let India Today in know that polluted water utilized in humidifiers, unsterilised gear and non-clinical grade oxygen chambers could likewise assume a potential part. In the subsequent wave, modern oxygen has been redirected for clinical use. We have seen these modern oxygen chambers, which are not clinical grade and inclined to spills, being moved in trucks and vans. In this way, cleanliness of chambers might have been compromised. Also, the water utilized in humidifier bottles through which oxygen is given should be sterile and clean. On the off chance that not, the danger of pollution increments by taking in parasitic spores [35] [36].

5. IMPLEMENTATIONS FROM VARIOUS AUTHORS

Table 1. Description and Causes of Mucormycosis

Authors	Causes (or) Methods	Descriptions
Antachopoulos C [1]	Fungal and Non culture diagnostic	The Diagnosis and treatment of Human mycoses (Fungal infection),
Alastruey-Izquierdo A [2]	saprotrophic fungi inhabiting soil or dead plant material	One of the major cause of Black fungus
Roilides E [6]	Diagnostic and therapeutic approach like Polymerase chain rection and hyperbaric oxygen etc.,	Awareness on children zygomycosis and comparasion with adult mycosis
Aditya Moorthy [10]	Aggressive maxillofacial and rhino-cerebro-orbital fungal infections	Corticosteroids have determined as an life-saver in many areas of Covid-19
Deepak Garg [20]	Diabetics with severe Covid	Development of Mucormycosis after severe COVID 19 with Diabetics.
Sen M [24]	underwent endoscopic sinus debridement	Usage of Corticosteriods increase the risk of invasive fungal infection.
Sharma S [28]	Imaging of intra orbital of mucormycosis	After Covid, many life threatening diseases like renal failure, diabetics, hypertension and black fungus are caused
Amanda Werthman-Ehrenreich [31]	rhino-orbital-cerebral mucormycosis with symptoms of hypertension and Asthma	Orbital Compartment Syndrome which leads to retinal failure
Mekonnen ZK [33]	acute respiratory distress	Acute invasive fungal rhinosinusitis

	syndrome.	
Alekesyev K [34]	Pneumonia from 1 diabetes mellitus (T1DM)	Treatments with intravenous (IV) fluids and an insulin drip cures the rhinocerebral mucormycosis
Andre K. Johnson [35]	rapid tissue destruction and invasion across tissueplanes	combined pulmonary aspergillosis and mucormycosis are considered as secondary complications of COVID-19 and treated as critically ill patients.
Khatri. A [37]	After few months of hearttransplants, the patients were diagnosed by COVID 19	In the Presence of Diabetics, immunosuppressive medications are used for the treatment.
Karimi. G [41]	Representation of acute sinusitis	Endoscopy treatment with insulin and systemic anti fungals
Veisi. A [42]	Causes are vision loss, proptosis, orbital inflammation, and complete ophthalmoplegia	Development of Rhino-orbital/cerebral mucormycosis
Zurl. C [45]	secondary pulmonary aspergillosis	Respiratory deterioration by imaging through highresolution CT

6. PREVENTION

It's hard to try not to take in parasitic spores on the grounds that the growths that cause mucormycosis are normal in the climate. There is no antibody to forestall mucormycosis. For individuals who have debilitated resistant frameworks, there might be a few methods for bringing down the possibilities creating mucormycosis.

- Shield yourself from the climate.
- Try to keep away from regions with a ton of residue like development or exhuming destinations. In theevent that you can't stay away from these region, wear a N95 respirator (a kind of facial covering) .
- Avoid direct contact with water-harmed structures and rising water after tropical storms and cataclysmicevents.
- Avoid exercises that include close contact to soil or residue, for example, yard work or planting.
- Wear shoes, long jeans, and a long-sleeved shirt while doing open air exercises, for example, planting, yardwork, or visiting lush regions.
- Wear gloves when dealing with materials like soil, greenery, or fertilizer.
- To decrease the possibilities fostering a skin disease, clean skin wounds well with cleanser

and water, particularly assuming they have been presented to soil or residue.

- Notwithstanding, a few gatherings are more powerless than others, Which inclines patients with uncontrolled diabetes mellitus, immunosuppression by steroids, delayed ICU stay, and comorbidities - post transfer/danger, voriconazole treatment. Specialists prompt that you use covers assuming you are visiting dusty building destinations. Wear shoes, long pants, long-sleeved shirts and gloves while dealing with soil (planting), greenery or compost. Keep up with individual cleanliness including a careful scour shower.[5]

7. TREATMENT

A person with mucormycosis needs a prescription antifungal medicine, most commonly amphotericin B, posaconazole, or isavuconazole. Antifungal medicine is usually administered through the vein (amphotericin B, posaconazole, isavuconazole) or through the mouth (posaconazole, isavuconazole). Many medicines do not work against the fungus that causes mucormycosis. Surgery may be necessary to cut away the infected tissue. Fluconazole, voriconazole, and echinocandins do not treat mucormycosis [37].

8. ANALYSIS OF BLACK FUNGUS

While it is analysed by antifungals, mucormycosis may ultimately require a medical procedure. Specialists have said that it is of most extreme significance to control diabetes, lessen steroid use, and stop immunomodulating drugs. To keep up with sufficient fundamental hydration, the treatment incorporates mixture of ordinary saline before implantation of amphotericin B and antifungal treatment, for somewhere around 4 a month and a half. Specialists in the team have focused on the need to control hyperglycemia, and screen blood glucose level after release following Covid-19 treatment, and furthermore in diabetics. One should utilize steroids sensibly - right planning, right portion and length are significant. The executives of Covid patients with mucormycosis is a collaboration including microbiologists, interior medication trained professionals, intensivist nervous system specialist, ENT subject matter experts, ophthalmologists, dental specialists, specialists (maxillofacial/plastic) and others. It relies upon the area of the speculated contamination [38]. An example of liquid from your respiratory framework might be gathered for testing in the lab; in any case a tissue biopsy or a CT output of your lungs, sinuses and so forth might be led.

8.1 Life after Surgery for Mucormycosis

Mucormycosis can prompt loss of the upper jaw and once in a while even the eye. "Patients would have to find a sense of peace with loss of capacity because of a missing jaw - trouble with biting, gulping, facial style and loss of confidence, specialists say. Be it the eye or upper jaw, these can be supplanted with proper counterfeit substitutes or prostheses. While prosthetic substitution of the missing facial constructions can initiate once the patient

balances out after a medical procedure, specialists it is critical to console him about the accessibility of such intercessions as opposed to passing on him to freeze with the abrupt unanticipated misfortune, expanding a post-Covid stress issue which is as of now a reality," said by one of the maxillofacial prosthodontist. "Prosthetic recreation can be affected after a medical procedure, yet between time arrangements ought to be arranged even before a medical procedure of the jaws for better long haul results. Prosthetic reproduction can guarantee that the fix isn't more repulsive than the actual illness" [39].

Cases found frequently: These incorporate aggravation and redness around eyes and additionally nose, fever, migraine, hacking, windedness, horrendous heaves, and modified mental status. Cautioning signs can incorporate toothache, releasing of teeth, obscured or twofold vision with torment. Weak gatherings incorporate individuals who have medical conditions or take drugs that bring down the body's capacity to battle microorganisms and disorder. These incorporate those with diabetes, disease, or the individuals who have had an organ relocate [40][41][42].

9. CONCLUSION

Mucormycosis is normally known as dark parasite sickness. This disease principally targets diabetic and immunocompromised patients. As COVID-19 disease decays the insusceptibility of patients, so mucormycosis cases are likewise expanding because of inward breath of molds containing modern oxygen. In this review paper it is clearly stated about the symptoms and diseases spread on patients like diabetics and low immune system patients, prevention, treatment and analysis of this disease are discussed[43][44][45]. From this paper will help for those who are undergoing on research on black fungus and it will give an awareness and precautions of black fungus.

REFERENCES

1. Antachopoulos C, Gea-Banacloche JC, Walsh TJ. Zygomycosis (mucormycosis). In: Hospenthal DR, Rinaldi MG, eds. *Diagnosis and treatment of human mycoses*. New York, NY: Springer; 2008:227-243.
2. Alastruey-Izquierdo A, Hoffmann K, de Hoog GS, et al. Species recognition and clinical relevance of the zygomycetous genus *Lichtheimia* (syn. *Absidia* pro parte, *Mycocladius*). *J Clin Microbiol*. 2010 Jun;48(6):2154-70.
3. Gonzalez CE, Rinaldi MG, Sugar AM. Zygomycosis. *Infect Dis Clin North Am*. 2002 Dec;16(4):895-914.
4. Maravi-Poma E, Rodriguez-Tudela JL, de Jalon JG, et al. Outbreak of gastric mucormycosis associated with the use of wooden tongue depressors in critically ill patients. *Intensive Care Med*. 2004 Apr;30(4):724-8.
5. International Diabetes Federation. *Idf diabetes atlas*. Available online: <https://diabetesatlas.org/en/resources/>. [Accessed 10 June, 2021].
6. Rilides E, Zaoutis TE, Walsh TJ. Invasive zygomycosis in neonates and children. *Clin Microbiol Infect*. 2009 Oct;15(suppl5):50-4.
7. Prabhu RM, Patel R. Mucormycosis and entomophthoramycosis: a review of the clinical

- manifestations, diagnosis and treatment. *Clin Microbiol Infect*. 2004 Mar;10(suppl 1):31-47.
8. Spellberg B, Edwards J Jr, Ibrahim A. Novel perspectives on mucormycosis: pathophysiology, presentation, and management. *Clin Microbiol Rev*. 2005 Jul;18(3):556-69.
 9. Neblett-Fanfair R, Benedict K, Bos J, et al. Necrotizing cutaneous mucormycosis after a tornado in Joplin, Missouri, in 2011. *N Engl J Med*. 2012 Dec 6;367(23):2214-25.
 10. Moorthy A, Gaikwad R, Krishna S, et al. SARS-CoV-2, uncontrolled diabetes and corticosteroids-an unholy trinity in invasive fungal infections of the maxillofacial region? A retrospective, multi-centric analysis. *J Maxillofac Oral Surg*. 2021 Mar 6;1-8.
 11. John TM, Jacob CN, Kontoyiannis DP. When uncontrolled diabetes mellitus and severe COVID-19 converge: the perfect storm for mucormycosis. *J Fungi (Basel)*. 2021 Apr 15;7(4):2021 Apr 15;7(4):298.
 12. Reyes HM, Tingle EJ, Fenves AZ, et al. Pulmonary invasive mucormycosis in a patient with secondary iron overload following deferoxamine therapy. *Proc (Bayl Univ Med Cent)*. 2008 Oct;21(4):378-81.
 13. Sahin B, Paydas S, Cosar E, et al. Role of granulocyte colony-stimulating factor in the treatment of mucormycosis. *Eur J Clin Microbiol Infect Dis*. 1996 Nov;15(11):866-9.
 14. Sugar AM. Agents of mucormycosis and related species. In: Mandell GL, Bennett JE, Dolin R, eds. *Principles and practice of infectious diseases*. 6th ed. Philadelphia, PA: Churchill Livingstone; 2005:2973-81.
 15. El Deeb Y, Al Soub H, Almaslamani M, et al. Post-traumatic cutaneous mucormycosis in an immunocompetent patient. *Ann Saudi Med*. 2005 Jul-Aug;25(4):343-5.
 16. Elsiey H, Saad M, Shorman M, et al. Invasive mucormycosis in a patient with liver cirrhosis: case report and review of the literature. *Hepat Mon*. 2013 Aug 11;13(8):e10858.
 17. Kontoyiannis DP, Lionakis MS, Lewis RE, et al. Zygomycosis in a tertiary-care cancer center in the era of Aspergillus-active antifungal therapy: a case-control observational study of 27 recent cases. *J Infect Dis*. 2005 Apr 15;191(8):1350-60.
 18. Roden MM, Zaoutis TE, Buchanan WL, et al. Epidemiology and outcome of zygomycosis: a review of 929 reported cases. *Clin Infect Dis*. 2005 Sep 1;41(5):634-53.
 19. Mehta S, Pandey A. Rhino-orbital mucormycosis associated with COVID-19. *Cureus* 2020 Sep 30;12(9). e10726.
 20. Garg D, Muthu V, Sehgal IS, Ramachandran R, et al. Coronavirus disease (Covid-19) associated mucormycosis (CAM): case report and systematic review of literature. *Mycopathologia* 2021 May;186(2):289e98.
 21. Maini A, Tomar G, Khanna D, Kini Y, Mehta H, Bhagyasree V. Sino-orbital mucormycosis in a COVID-19 patient: a case report. *Int J Surg Case Rep* 2021, May 4;82:105957.
 22. Saldanha M, Reddy R, Vincent MJ. Title of the article: paranasal mucormycosis in COVID-19 patient. *Indian J Otolaryngol Head Neck Surg* 2021 Apr 22;1e4. <https://doi.org/10.1007/s12070-021-02574-0> [Online ahead of print].
 23. Revannavar SM, PS S, Samaga L. COVID-19 triggering mucormycosis in a susceptible patient: a new phenomenon in the developing world? *BMJ Case Rep* 2021 Apr 27;14(4). e241663.
 24. Sen M, Lahane S, Lahane TP, et al. Mucor in a viral land: a tale of two pathogens. *Indian J Ophthalmol* 2021;69:244e52.

25. Sarkar S, Gokhale T, Choudhury SS, Deb AK. COVID-19 and orbital mucormycosis. *Indian J Ophthalmol* 2021 Apr;69(4):1002e4.
26. Mishra N, Mutya VSS, Thomas A, et al. A case series of invasive mucormycosis in patients with COVID-19 infection. *Int J Otorhinolaryngol Head Neck Surg* 2021 May;7(5):867e70.
27. Satish D, Joy D, Ross A, Balasubramanya. Mucormycosis coinfection associated with global COVID-19: a case series from India. *Int J Otorhinolaryngol Head Neck Surg* 2021 May;7(5):815e20.
28. Sharma S, Grover M, Bhargava S, Samdani S, Kataria T. Post coronavirus disease mucormycosis: a deadly addition to the pandemic spectrum. *J Laryngol Otol* 2021 Apr 8;1e6. <https://doi.org/10.1017/S0022215121000992> [Online ahead of print].
29. Hanley B, Naresh KN, Roufousse C, et al. Histopathological findings and viral tropism in UK patients with severe fatal COVID-19: a post-mortem study. *Lancet Microbe* 2020 Oct;1(6):e245e53.
30. Dallalzadeh LO, Ozzello DJ, Liu CY, Kikkawa DO, Korn BS. Secondary infection with rhino-orbital cerebral mucormycosis associated with COVID-19. *Orbit* 2021 Mar 23;1e4. <https://doi.org/10.1080/01676830.2021.1903044> [Online ahead of print].
31. Werthman-Ehrenreich A. Mucormycosis with orbital compartment syndrome in a patient with COVID-19. *Am J Emerg Med* 2021;42:264. e5e264.e8, In press.
32. Placik DA, Taylor WL, Wnuk NM. Bronchopleural fistula development in the setting of novel therapies for acute respiratory distress syndrome in SARS-CoV-2 pneumonia. *Radiol Case Rep* 2020 Nov;15(11):2378e81.
33. Mekonnen ZK, Ashraf DC, Jankowski T, et al. Acute invasive rhino-orbital mucormycosis in a patient with COVID-19-associated acute respiratory distress syndrome. *Ophthalmic Plast Reconstr Surg* 2021;37. e40e80.
34. Alekesyev K, Didenko L, Chaudhry B. Rhinocerebral mucormycosis and COVID-19 pneumonia. *J Med Cases* 2021;12(3):85e9.
35. Johnson AK, Ghazarian Z, Cendrowski KD, Persichino JG. Pulmonary aspergillosis and mucormycosis in a patient with COVID-19. *Med Mycol Case Rep* 2021 Jun;32:64e7.
36. Kanwar A, Jordan A, Olewiler S, Wehberg K, Cortes M, Jackson BR. A fatal case of *Rhizopus azygosporus* pneumonia following COVID-19. *J Fungi (Basel)* 2021 Feb 28;7(3):174.
37. Khatri A, Chang KM, Berlinrut I, Wallach. Mucormycosis after Coronavirus disease 2019 infection in a heart transplant recipient - case report and review of literature. *J Mycol Med* 2021 Apr 2;31(2):101125.
38. Monte Junior ESD, Santos MELD, Ribeiro IB, et al. Rare and fatal gastrointestinal mucormycosis (zygomycosis) in a COVID-19 patient: a case report. *Clin Endosc* 2020 Nov;53(6):746e9.
39. Pasero D, Sanna S, Liperi C, et al. A challenging complication following SARS-CoV-2 infection: a case of pulmonary mucormycosis. *Infection* 2020;1e6.
40. Bellanger AP, Navellou JC, Lepiller Q, et al. Mixed mold infection with *Aspergillus fumigatus* and *Rhizopus microsporus* in a severe acute respiratory syndrome Coronavirus 2 (SARS-CoV-2) patient. *S2666-9919(21)00030-0 Infect Dis News* 2021 Jan 27. <https://doi.org/10.1016/j.idnow.2021.01.010> [Online ahead of print].

41. Karimi-Galougahi M, Arastou S, Haseli S. Fulminant mucormycosis complicating coronavirus disease 2019 (COVID-19). *Int Forum Allergy Rhinol* 2021 Mar 13. <https://doi.org/10.1002/alr.22785> [Online ahead of print].
42. Veisi A, Bagheri A, Eshaghi M, Rikhtehgar MH, Rezaei Kanavi M, Farjad R. Rhino-orbital mucormycosis during steroid therapy in COVID-19 patients: a case report. *Eur J Ophthalmol* 2021 Apr 10. <https://doi.org/10.1177/11206721211009450> [Online ahead of print].
43. Sargin F, Akbulut M, Karaduman S, Sungurtekin H. Severe rhinocerebral mucormycosis case developed after COVID 19. *JBacteriol Parasitol* 2021;12: 386.
44. Waizel-Haiat S, Guerrero-Paz JA, Sanchez-Hurtado L, et al. A case of fatal rhino-orbital mucormycosis associated with new onset diabetic ketoacidosis and COVID-19. *Cureus* 2021;13. e13163.
45. Zurl C, Hoenigl M, Schulz E, et al. Autopsy proven pulmonary mucormycosis due to *Rhizopus microsporus* in a critically ill COVID-19 patient with underlying hematological malignancy. *J Fungi (Basel)*. 2021 Jan 27;7(2):88.